

Resection and Mediastinal Lymph Node Dissection

Alexander H. Moskovitz, MD, and Valerie W. Rusch, MD

Mediastinal lymph node assessment is an essential component of the surgical management of lung cancer. Traditionally, a potentially curative resection is considered to involve the complete resection of the primary tumor with microscopically benign resection margins, and a systematic dissection of lymphatic drainage to accessible mediastinal nodes. Defining the extent of lymph node involvement is important for accurate staging and prognostic guidance. Accurate lymph node assessment also guides the decision to use adjuvant therapy after resection.

In the management of lung cancer, several approaches are used to evaluate the extent of mediastinal lymph node involvement. Cervical mediastinoscopy and parasternal mediastinotomy are frequently performed to determine if metastatic disease is present in the mediastinal lymph nodes and whether patients should undergo primary resection. When performing mediastinoscopy, we routinely use a video-assisted mediastinoscopic technique; this technique has been demonstrated to have a very high specificity for the absence of mediastinal metastasis.¹ At thoracotomy, systematic mediastinal lymph node sampling (SS), which involves the biopsy of lymph nodes at each of the ipsilateral thoracic mediastinal lymph node stations, can be performed and is considered the minimally acceptable approach to intraoperative staging (see Fig 1). Alternatively, complete mediastinal lymph node dissection (MLND), which includes removal of all mediastinal nodes within the ipsilateral hemithorax (paratracheal and/or subaortic, subcarinal, and nodes near the inferior pulmonary ligament) provides a more complete assessment of lymph node involvement. Extended lymph node dissection refers to excision of lymph nodes beyond the ipsilateral hemithorax, or the use of a separate incision to complete a nodal excision. As part of a potentially curative resection for lung cancer, we routinely perform a complete MLND.

Our technique of MLND was initially described by Cahan and further refined by Martini.²⁻⁴ In general, we perform MLND as the first step of the operation, submitting the lymph nodes for frozen section to confirm that the planned pulmonary resection is appropriate. The dissection is generally safe and easy to do, adding approximately 20 to 30 minutes of

operative time without added morbidity.⁵ The presence of mediastinal nodal metastases that have bypassed or “skipped” intrapulmonary (N1 station) nodes can occur in up to 38% of patients, which makes the staging of mediastinal nodal stations a mandatory component of the intraoperative evaluation of a lung cancer.^{6,7} When compared with SS, MLND identifies more levels of mediastinal nodal metastasis (N2 disease).⁸ Defining this multilevel degree of metastasis has prognostic importance. As many as one third of patients with mediastinal nodal disease may have only 1 node involved.⁹ In surgically resected patients who undergo an MLND with mediastinal nodal metastasis confined to 1 node, 5-year survival may be as high as 43%.⁹⁻¹¹ This is improved survival compared with multilevel metastasis.⁹ In those patients with a limited burden of local-regional nodal metastasis, resection of mediastinal nodes may improve survival.^{8,12} Thus, complete MLND at least accurately defines the extent of disease and may improve survival in some patients.^{13,14} The results of a recent prospective, randomized, multicenter North American trial confirm the safety of MLND relative to SS.¹⁵ Long-term follow-up from this trial will be required to determine whether MLND confers a survival benefit in patients with stages I and II non-small cell lung cancer.

With the development of minimally invasive approaches to the surgical resection of lung cancer, we have continued to apply our goals of complete MLND. Video-assisted thoracic surgery (VATS) lobectomy has become a viable treatment option for patients with early stage lung cancer, especially clinical stage IA.^{16,17} Potential advantages include shorter length of stay, less postoperative pain, more rapid recovery with return to full activity, and lower overall cost. Although the surgical approach to node dissection is similar, the technical challenges of VATS involve a learning curve.¹⁶⁻¹⁹ To lessen the chance of insufficient mediastinal node resection in the VATS management of a lung cancer, one may¹ do routine meticulous cervical mediastinoscopy and/or² limit thoracoscopic dissection to patients with smaller tumors (<2.0 cm). The prevalence of mediastinal nodal metastasis for patients with a tumor less than 2 cm in size ranges from 0% to 12%.^{20,21} Meticulous mediastinoscopy and limiting VATS lobectomy to patients with tumors 2.0 cm or less in size is a reasonable approach for surgeons gaining proficiency with a thoracoscopic approach to MLND. As experience is gained in performing VATS lobectomies, it is possible to perform an MLND thoracoscopically, and this has now become our routine approach.

Thoracic Service, Department of Surgery, Memorial Sloan-Kettering Cancer Center, New York, NY.

Address reprint requests to Valerie W. Rusch, MD, Thoracic Service, Department of Surgery, Memorial Sloan-Kettering Cancer Center, 1275 York Avenue, New York, NY 10021. E-mail: ruschv@mskcc.org

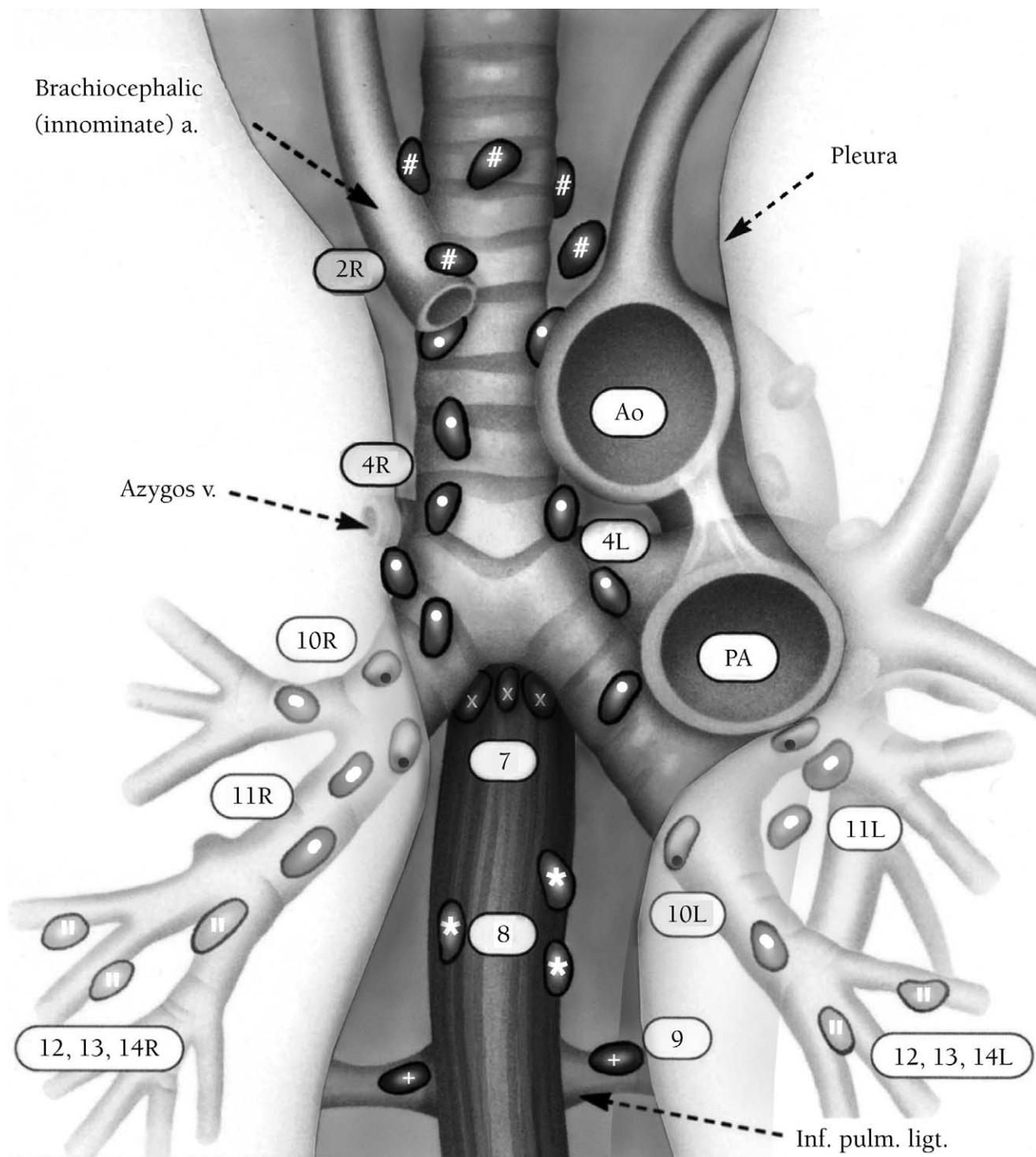


Figure 1 Lymph node map. At thoracotomy, the MLND should involve a complete assessment of ipsilateral thoracic mediastinal nodes. Right lung cancers should have right level 4 and level 7 nodes removed. Left lung cancers should have level 5/6 and level 7 nodes dissected routinely. For left lower lobe tumors, we selectively perform cervical mediastinoscopy to assess right level 4 nodes because of the documented propensity of these cancers to metastasize to the right paratracheal lymph nodes.

In summary, we routinely perform an MLND in the assessment of all patients undergoing curative resection for non-small cell carcinoma of the lung. We believe our approach provides accurate and complete staging information without added morbidity. MLND may improve survival in some patients with limited regional nodal disease, but definitive data regarding this issue are not yet available.

Surgical Techniques

Postoperative Considerations

Potential complications of MLND compared with more limited SS include increased blood loss with more transfusion requirement, bronchial devascularization with increased risk of bronchial stump fistula, injury to the recurrent laryngeal

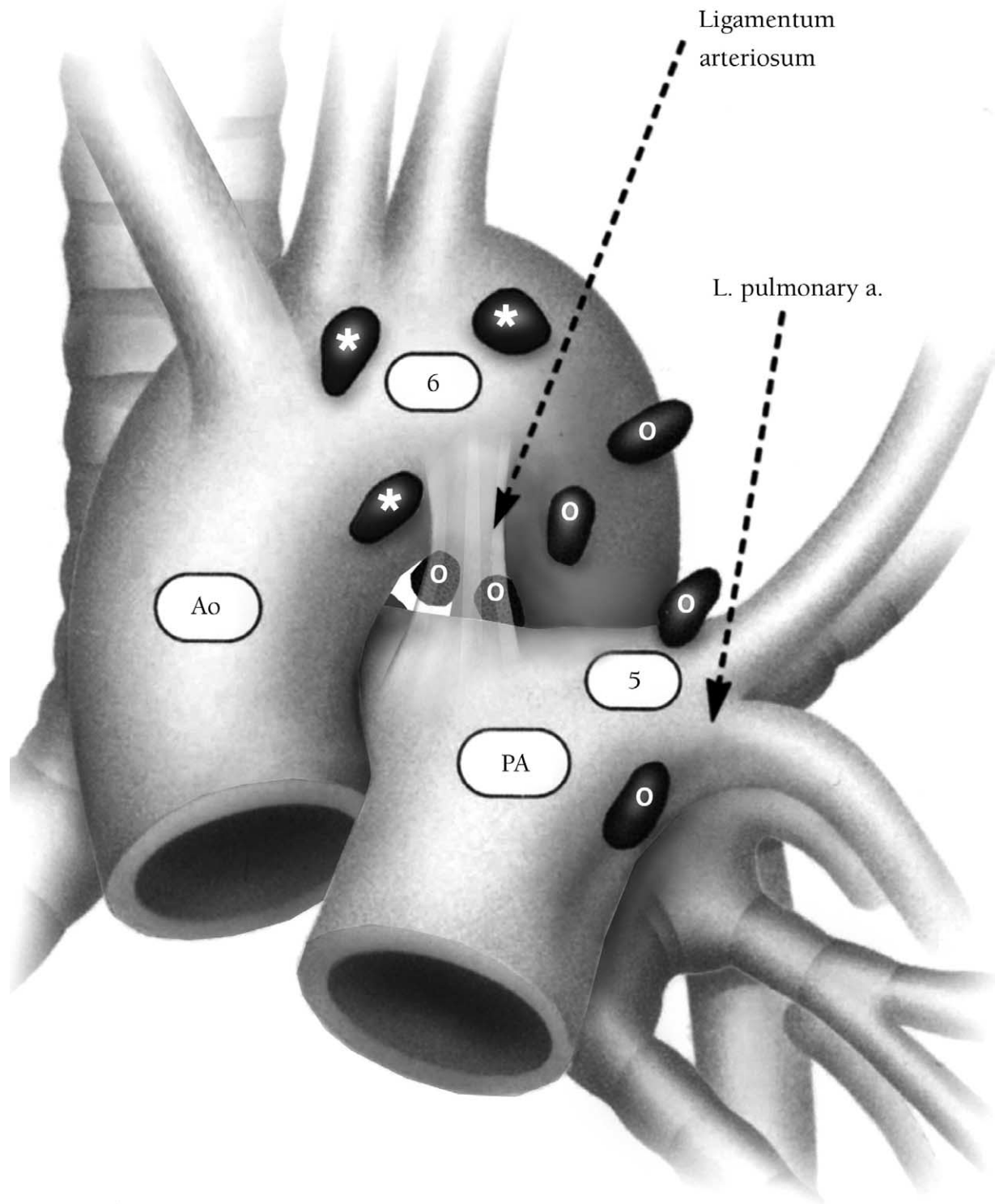


Figure 2 Lymph node map of levels 5 and 6: the aortopulmonary “window” nodes. Resection of level 5 and 6 nodes is part of the standard lymph node dissection in patients with left lung tumors, especially left upper lobe carcinomas. Care must be taken not to injure the left recurrent laryngeal nerve during the dissection of level 5 lymph nodes.

nerve, and lymphatic disruption with chylothorax. No difference has been reported in operating time, blood loss, transfusion requirement, or bronchial stump fistula in patients undergoing MLND compared with SS.^{8,15} Recurrent laryngeal nerve injury and chylothorax have been reported after MLND.²² When metastatic adenopathy in the left hilum involves the recurrent laryngeal nerve, we sacrifice the nerve to obtain complete resection of disease. In these cases, vocal

cord function is assessed by indirect laryngoscopy 48 to 72 hours postoperatively to evaluate the need for vocal cord medialization. With liberal use of surgical clips and meticulous sharp dissection around the location of the recurrent nerve, the risks of both nerve injury and lymphatic leak can be minimized. As mentioned previously, MLND adds no more than 30 minutes to overall operative time.

Some thoracic surgeons have advocated a more aggressive

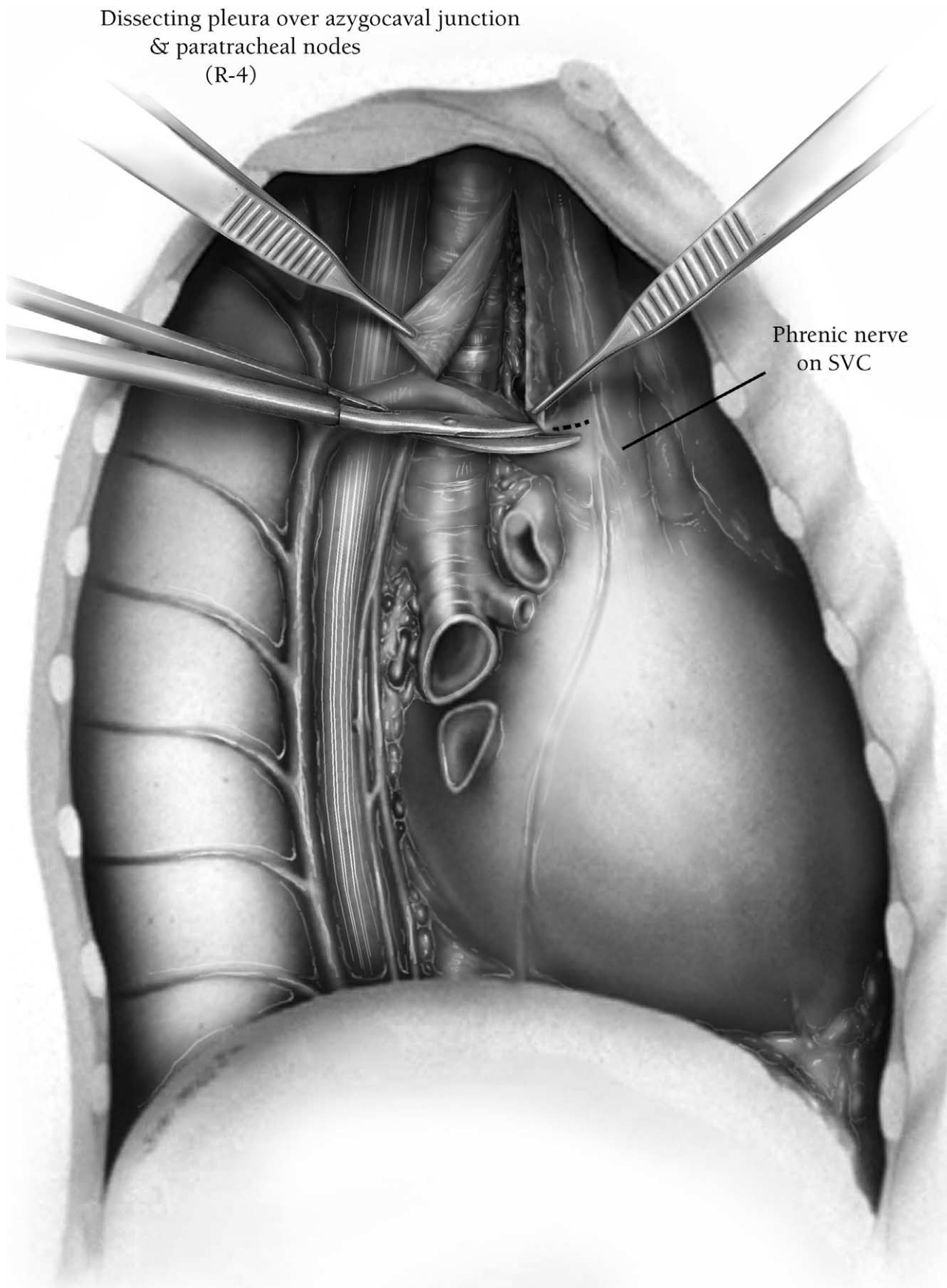


Figure 3 View of the right paratracheal lymph node dissection (level 4R). The pleura is incised vertically from the azygos vein to the innominate artery at a point halfway between the trachea and the superior vena cava. The incision can be extended horizontally, parallel to the azygos vein, to improve exposure. For patients who have received preoperative chemotherapy or chemoradiotherapy, it is helpful to divide the azygos vein to facilitate exposure to the inferior portion of the right paratracheal region and the right main pulmonary artery.

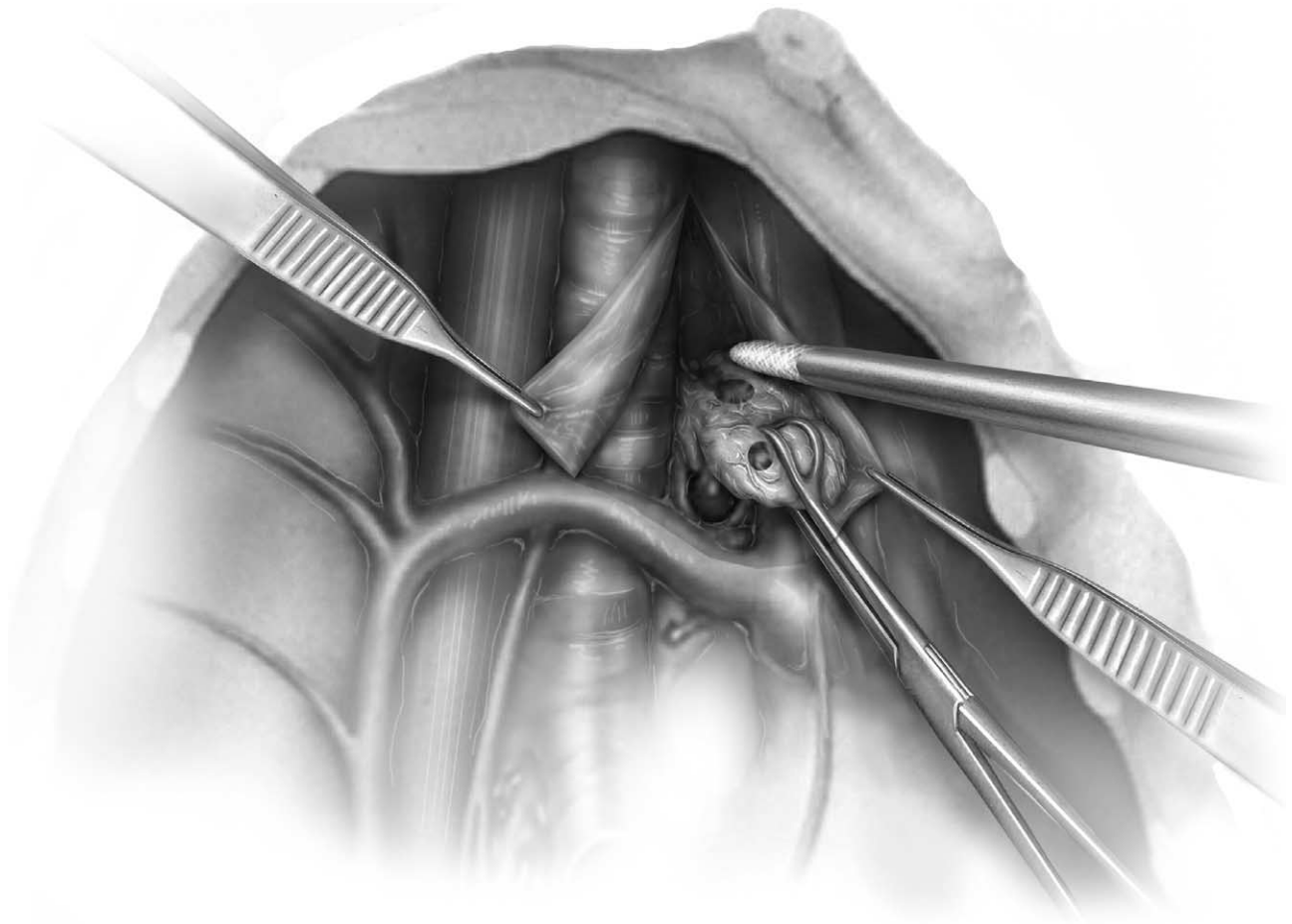


Figure 4 Close-up view of the dissection of the right paratracheal lymph nodes (level 4R). The entire nodal packet extending from the innominate artery superiorly to the tracheobronchial angle inferiorly is removed. As shown, the incised pleura is reflected away from the nodes, and the nodal packet is grasped with a sponge stick or Babcock clamp. Sharp or blunt dissection is used to sweep the nodes away from the superior vena cava anteriorly and from the trachea posteriorly. A small vein draining from the nodal packet into the superior vena cava anteriorly should be identified and carefully ligated, as should a small branch of the vagus nerve posteriorly. Care is taken not to injure the origin of the right recurrent laryngeal nerve at the level of the innominate artery superiorly. Surgical clips are used liberally to control vessels and lymphatic channels entering the nodal packet. Less bleeding is encountered if the nodal packet is removed en bloc rather than piecemeal. Inferiorly, dissection is carried under the azygos vein, sweeping the lymph nodes up from this area. The deep margin of the dissection is the pericardium overlying the ascending aorta.

approach to lymphadenectomy than what we have presented. A more extended lymphadenectomy can involve mobilization of the aortic arch to obtain left paratracheal nodes.²³ Alternatively, some have advocated median sternotomy for dissection of paratracheal lymph nodes both ipsilateral and contralateral to the tumor.^{24,25} At this time, we remain unconvinced of the therapeutic advantages of extended lymph node dissection and are concerned about its potential increased morbidity. This remains an area for further investigation.

We routinely perform a complete MLND in all patients undergoing curative resection for non-small cell carcinoma of the lung. We believe our approach provides complete staging information and may improve survival in some patients with limited regional disease. When performing a thoracoscopic lobectomy, we continue to apply our principles of complete MLND. Carefully performed, a complete MLND has virtually no added morbidity and is accurate care of the patient undergoing lung resection for cancer cure.

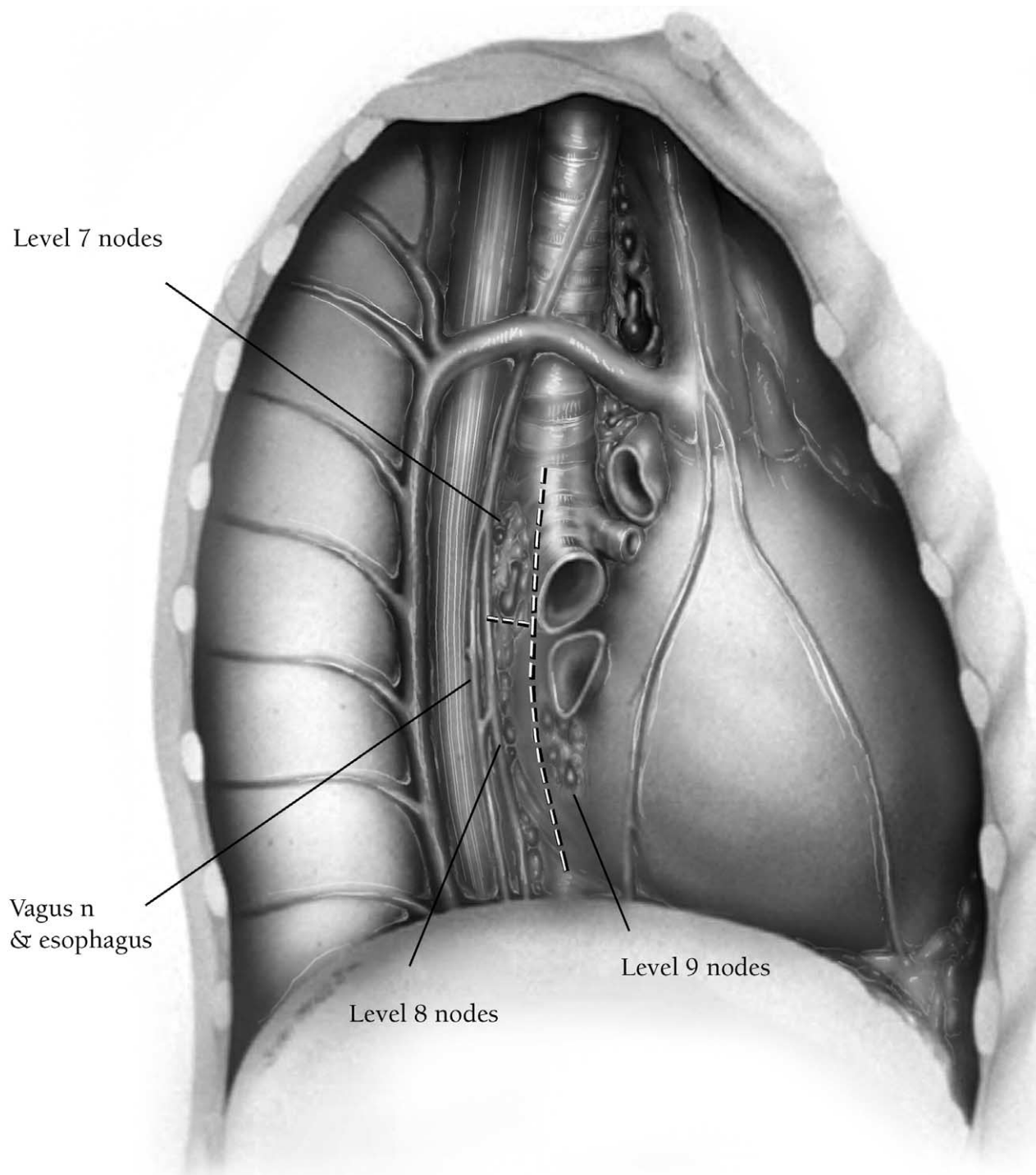


Figure 5 Right mediastinal view, inferior compartment. The posterior mediastinal pleura is incised vertically from the level of the main-stem bronchus to the inferior pulmonary ligament. This exposes the subcarinal, paraesophageal, and inferior pulmonary ligament nodes.

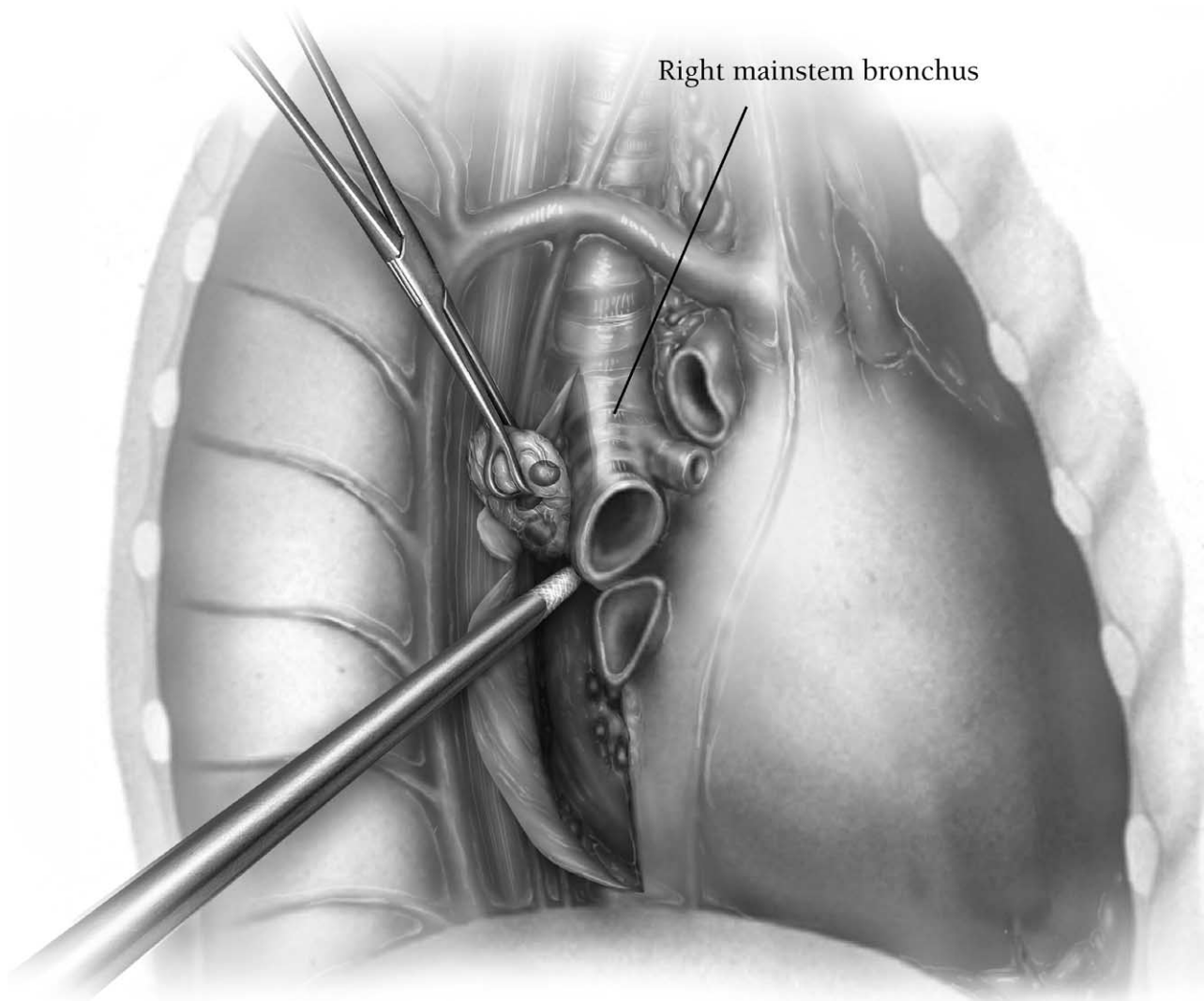


Figure 6 View of the subcarinal lymph node dissection. The subcarinal nodal packet is grasped with a sponge stick and is dissected off the right main-stem bronchus cranially up toward the carina. Anteriorly, the nodes are swept away from the pericardium with either blunt or sharp dissection. Posteriorly, the nodal packet is dissected off the esophagus. Surgical clips are used liberally to control feeding bronchiolar arterioles encountered at the main carina. Dissection is completed by sweeping the nodal packet away from the left main-stem bronchus, so that the entire packet is removed en bloc.

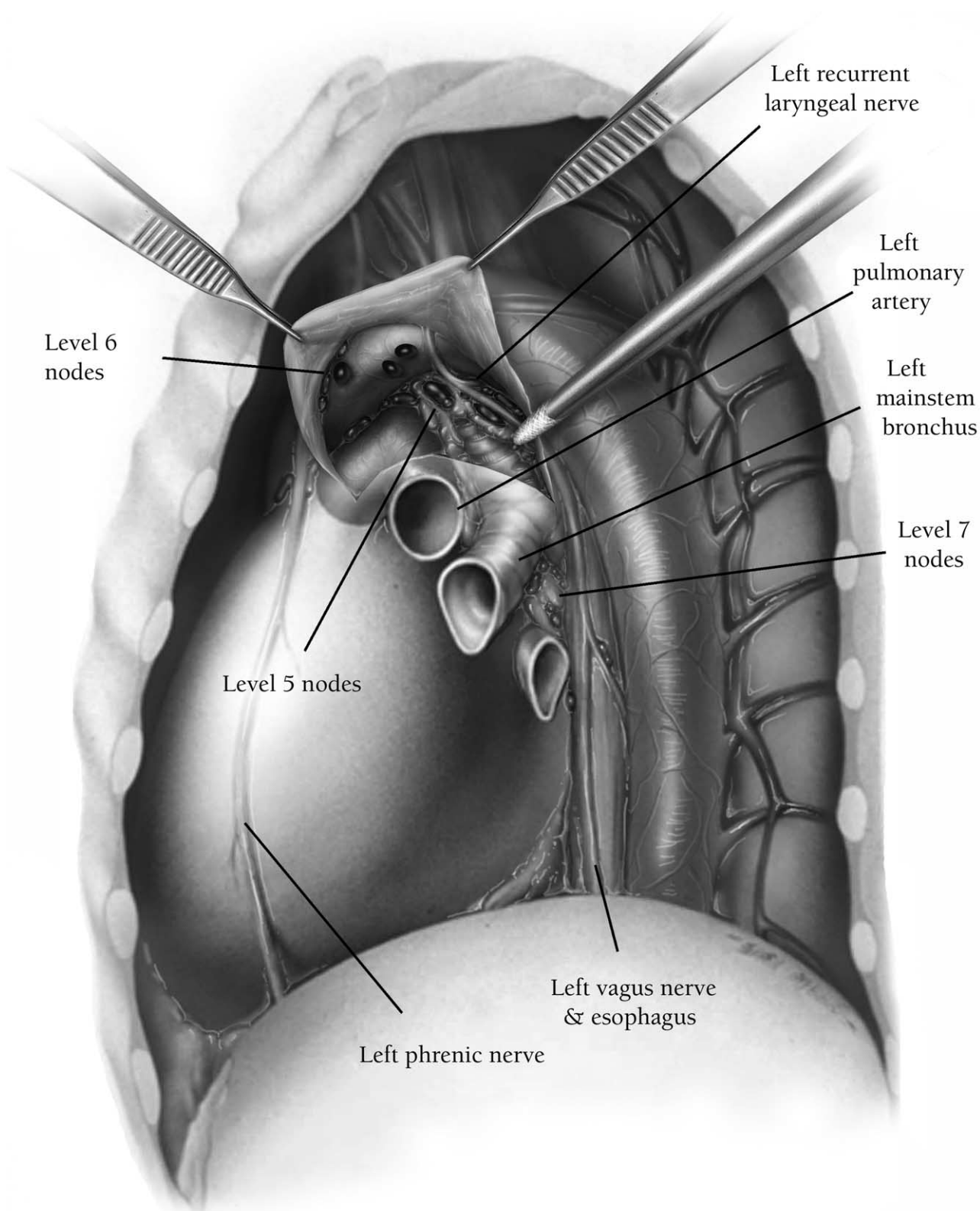


Figure 7 View of the aortopulmonary window dissection. The pleura is circumferentially incised around the superior aspect of the pulmonary hilum, exposing the aortic arch, the left main pulmonary artery, the phrenic nerve, the vagus nerve, and the origin of the left recurrent laryngeal nerve.

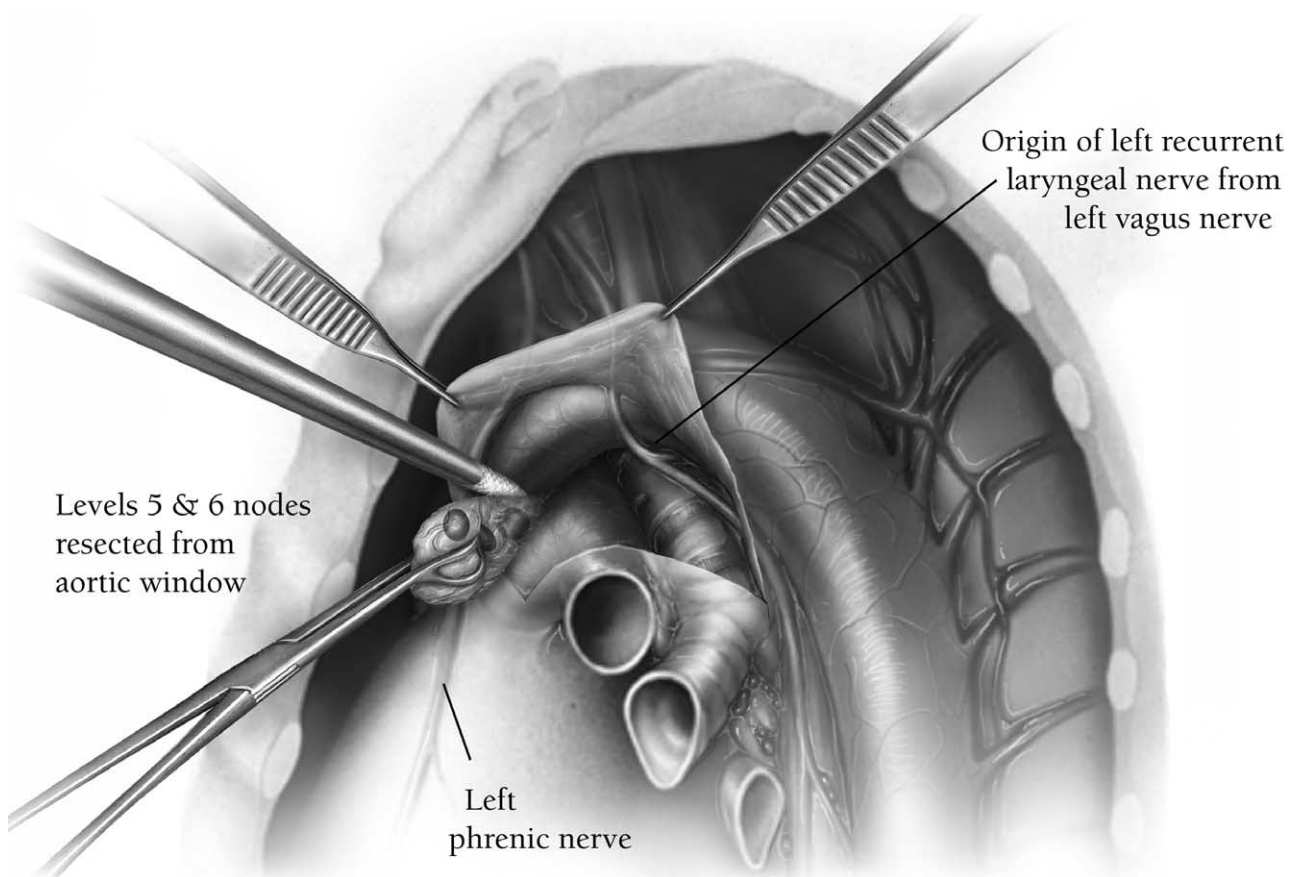


Figure 8 The levels 5 and 6 lymph nodes are swept away from the aortic arch, the left main pulmonary artery, and the phrenic and vagus nerves with blunt or sharp dissection. Care is taken not to injure the origin of the left recurrent laryngeal nerve. Surgical clips are liberally used to control all vessels and lymphatic channels.

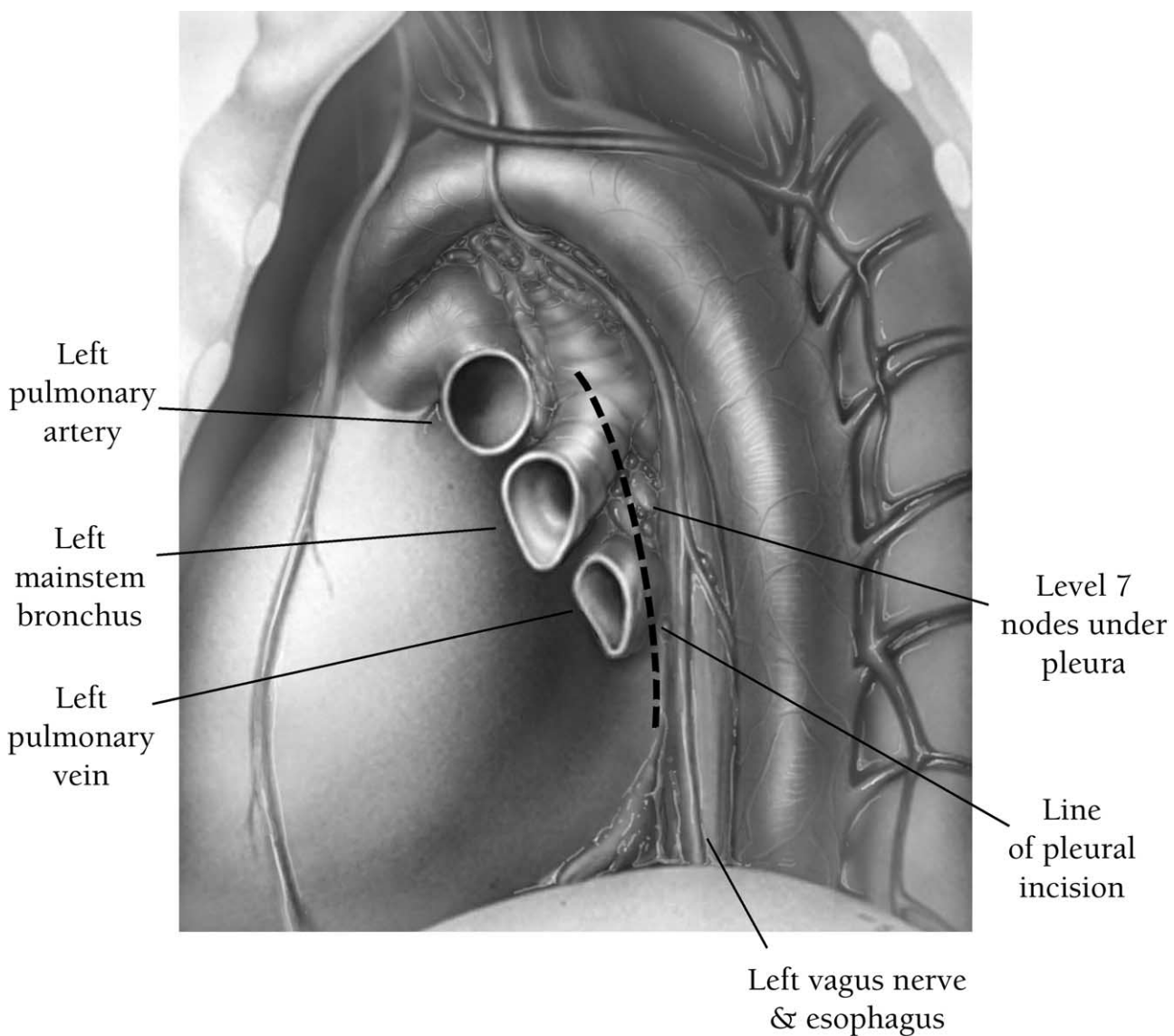


Figure 9 Subcarinal and inferior mediastinal view from the left side. The pleura is incised along the posterior aspect of the hilum down to the inferior pulmonary ligament, exposing the subcarinal, paraesophageal, and inferior pulmonary ligament nodes.

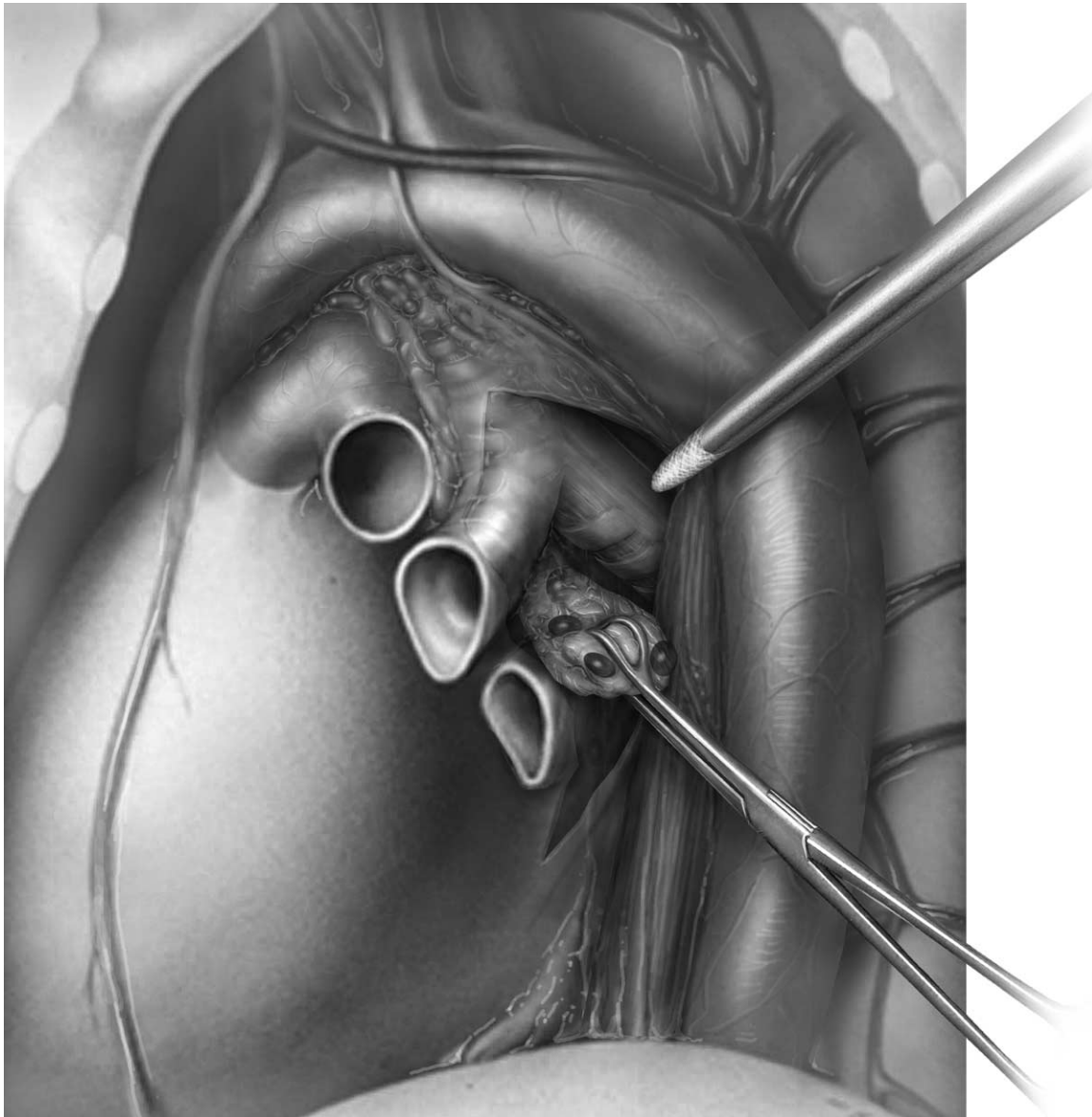

Figure 10 Dissection of the subcarinal nodes from the left side. The nodal packet is dissected off the left main-stem bronchus cranially up to the main carina. Anteriorly, the nodal packet is swept off of the pericardium, and anteriorly, it is mobilized away from the esophagus with blunt or sharp dissection. Access to the carina is more difficult on the left side than on the right side because of the aorta. Gentle retraction of the lung anteriorly helps to pull the left main-stem bronchus into the operative field while maintaining exposure. A narrow malleable retractor can be used to retract the esophagus and aorta and provide good exposure of the subcarinal space. Care is taken to ligate the feeding bronchiolar arteries that enter the nodal packet at the main carina. The dissection is completed by sweeping the nodes away from the right main-stem bronchus and removing the entire subcarinal nodal packet en bloc.

References

1. Leschber G, Holinka G, Linder A: Video-assisted mediastinoscopic lymphadenectomy (VAMLA)—a method for systematic mediastinal lymph node dissection. *Eur J Cardiothorac Surg* 24:192-195, 2003
2. Cahan WG: Radical lobectomy. *J Thorac Cardiovasc Surg* 39:555-572, 1960
3. Cahan WG, Watson WL, Pool JL: Radical pneumonectomy. *J Thorac Cardiovasc Surg* 22:449-473, 1951
4. Martini N: Mediastinal lymph node dissection for lung cancer. The Memorial experience. *Chest Surg Clin N Am* 5:189-203, 1995
5. Izbicki JR, Thetter O, Habekost M, et al: Radical systematic mediastinal lymphadenectomy in non-small cell lung cancer: A randomized controlled trial. *Br J Surg* 81:229-235, 1994
6. Prenzel KL, Monig SP, Sinning JM, et al: Role of skip metastasis to mediastinal lymph nodes in non-small cell lung cancer. *J Surg Oncol* 82:256-260, 2003
7. Tateishi M, Fukuyama Y, Hamatake M, et al: Skip mediastinal lymph node metastasis in non-small cell lung cancer. *J Clin Oncol* 57:139-142, 1994
8. Keller SM, Adak S, Wagner H, et al: Mediastinal lymph node dissection improves survival in patients with stages II or IIIa non-small cell lung cancer. *Ann Thorac Surg* 70:358-366, 2000
9. Martini N, Flehinger BJ: The role of surgery in N2 lung cancer. *Surg Clin N Am* 67:1037-1049, 1987
10. Keller SM, Vangel MG, Wagner H, et al: Prolonged survival in patients with resected non-small cell lung cancer and single-level N2 disease. *J Thorac Cardiovasc Surg* 128:130-137, 2004
11. Patterson GA, Piazza D, Pearson FG, et al: Significance of metastatic disease in subaortic lymph nodes. *Ann Thorac Surg* 43:155-159, 1987
12. Izbicki JR, Passlick B, Pantel K, et al: Effectiveness of radical systematic mediastinal lymphadenectomy in patients with resectable non-small cell lung cancer. *Ann Surg* 227:138-144, 1998

13. Naruke T, Goya T, Tshuchiya R, et al: The importance of surgery to non-small cell carcinoma of lung with mediastinal lymph node metastasis. *Ann Thorac Surg* 46:603-610, 1988
14. Watanabe Y, Shimizu J, Oda M, et al: Aggressive surgical intervention in N2 non-small cell cancer of the lung. *Ann Thorac Surg* 51:253-261, 1991
15. Allen MS, Darling GE, Pechet TTV, et al: Morbidity and mortality of major pulmonary resections in patients with early stage lung cancer: Initial results of the randomized, prospective ACOSOG Z0030 trial. *Ann Thorac Surg*. In press
16. Daniels LJ, Balderson SS, Onaitis MW, et al: Thoracoscopic lobectomy: A safe and effective strategy for patients with stage I lung cancer. *Ann Thorac Surg* 74:860-864, 2002
17. McKenna RJ, Jr.: Lobectomy by video-assisted thoracic surgery with mediastinal node sampling for lung cancer. *J Thorac Cardiovasc Surg* 107:879-882, 1994
18. McKenna RJ, Jr.: Thoracoscopic lobectomy with mediastinal sampling in 80-year-old patients. *Chest* 106:1902-1904, 1994
19. Kaseda S, Hangai N, Yamamoto S, et al: Lobectomy with extended lymph node dissection by video-assisted thoracic surgery for lung cancer. *Surg Endosc* 11:703-706, 1997
20. Watanabe S, Oda M, Tsunozuka Y, et al: Peripheral small-sized (2 cm or less) non-small cell lung cancer with mediastinal lymph node metastasis: Clinicopathologic features and patterns of nodal spread. *Eur J Cardiothorac Surg* 22:995-999, 2002
21. Oda M, Watanabe Y, Shimizu J, et al: Extent of mediastinal node metastasis in clinical stage I non-small cell lung cancer: The role of systematic nodal dissection. *Lung Cancer* 22:23-30, 1998
22. Bollen ECM, van Duin CJ, Theunissen PHMH, et al: Mediastinal lymph node dissection in resected lung cancer: Morbidity and accuracy of staging. *Ann Thorac Surg* 55:961-966, 1993
23. Watanabe Y, Shimizu J, Oda M, et al: Improved survival in left non-small cell N2 lung cancer after more extensive operative procedure. *Thorac Cardiovasc Surg* 39:89-94, 1991
24. Hata E, Hayakawa K, Miyamoto H: Rationale for extended lymphadenectomy for lung cancer. *Theor Surg* 5:19-25, 1990
25. Hata E, Miyamoto H, Tanaka M: Superradical operation for lung cancer: Bilateral mediastinal dissection with or without cervical dissection. *Lung Cancer* 11(Suppl 2):41-42, 1994