

# Transaxillary First Rib Resection for Thoracic Outlet Syndrome

Harold C. Urschel, Jr., MD

## Introduction

Thoracic outlet syndrome, a term coined by Rob and Standeven,<sup>1</sup> refers to compression of the subclavian vessels and brachial plexus at the superior aperture of the chest. It was previously designated according to presumed compression etiologies such as scalenus anticus, costoclavicular, hyperabduction, cervical rib, and first thoracic rib syndromes. The various syndromes are similar, and the compression mechanism is often difficult to identify. Most compressive factors operate against the first rib (Fig. 1).

## Therapy

Most patients with thoracic outlet syndrome can be treated conservatively without surgery in a successful fashion. In general, patients with neurogenic thoracic outlet syndrome should be given physiotherapy when the diagnosis is made.

Proper physiotherapy includes heat massages, active neck exercises, stretching of the scalenus muscles, strengthening of the upper trapezius muscle, and posture instruction. Because sagging of the shoulder girdle, which is common among middle-aged people, is a major cause in this syndrome, many patients with less severe cases are improved by strengthening the shoulder girdle and by improving posture.

Most patients with thoracic outlet syndrome who have ulnar nerve conduction velocities (UNCVs) of more than 60 meters per second (mps) improve with conservative management.<sup>2</sup> If the conduction velocity is below that level, most patients, despite physiotherapy, may remain symptomatic, and surgical resection of the first rib and correction of other bony abnormalities may be needed to provide relief of symptoms.

If symptoms of neurovascular compression continue after physiotherapy, and the conduction velocity shows slight or no improvement or regression, surgical resection of the first rib and cervical rib, when present, should be considered.

The transaxillary route is an expedient approach for com-

plete removal of the first rib with decompression of the seventh and eighth cervical and first thoracic nerve roots and the lower trunks of the brachial plexus. First rib resection can be performed without the need for major muscle division, the need for retraction of the brachial plexus, and the difficulty of removing the posterior segment of the rib. In addition, first rib resection shortens the postoperative disability and provides better cosmetic results than the anterior and posterior approaches, particularly because 80% of patients are female.

## The Appropriate Surgical Approach

The supraclavicular approach in our practice is used primarily for arterial lesions requiring control of the proximal subclavian artery for either resection of aneurysm or stenosis and bypass graft placement.<sup>3</sup> The transaxillary approach is reserved for intermittent or total axillary-subclavian venous occlusion (Paget-Schroetter Syndrome)<sup>4,5</sup> neurological compression,<sup>6</sup> or combinations of these. The posterior approach, in our hands, is used for reoperation requiring neurolysis of the brachial plexus and decompression of vascular structures.<sup>7</sup> Dorsal sympathectomy may be conducted concomitantly or separately through any of the three incisions when indicated for sympathetic maintained pain management or hyperhidrosis.<sup>8</sup>

## Transaxillary First Rib Resection

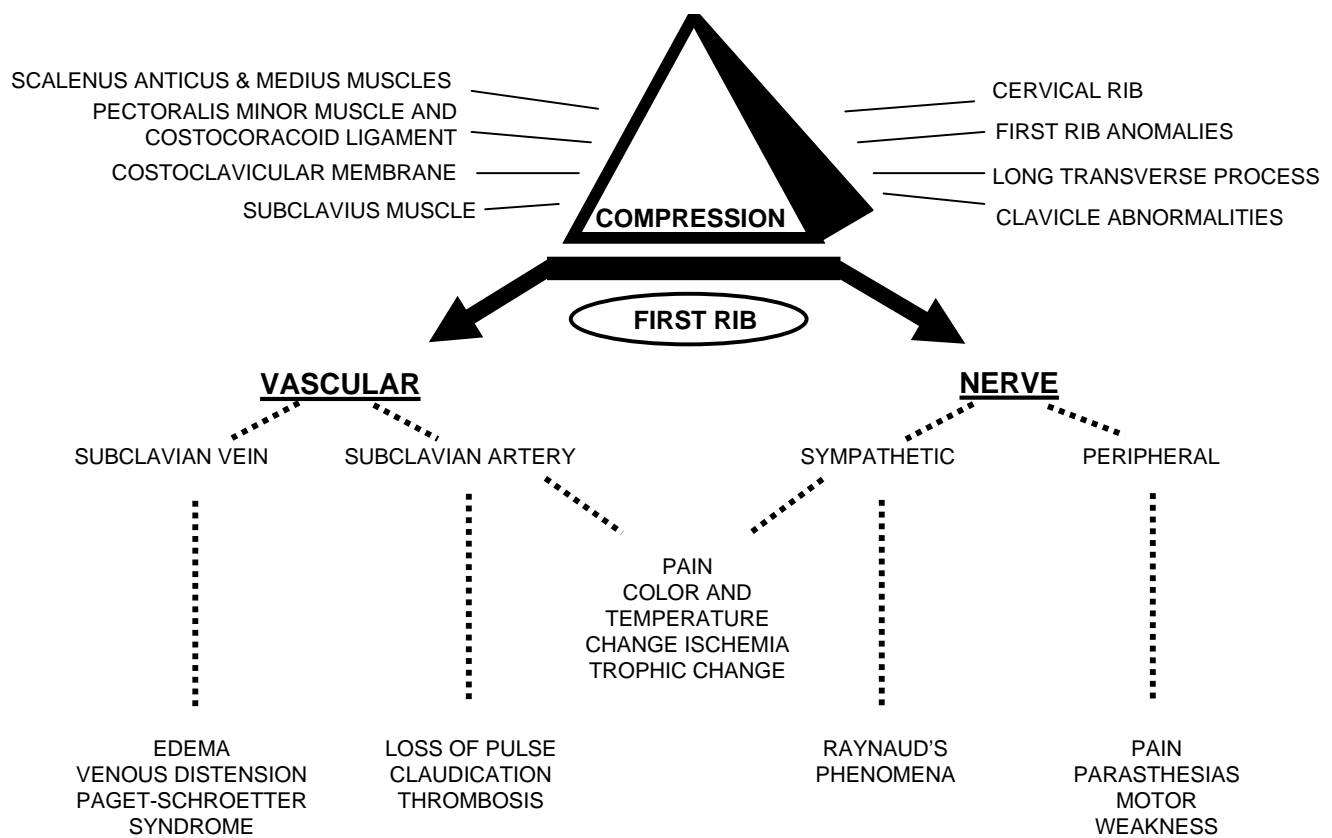
The advantage of this approach is that the rib can be removed and the thoracic outlet decompressed without working through or retracting the brachial plexus and axillary-subclavian blood vessels. A double-lumen tube is employed to collapse the lung on the operative side, minimizing the chance for an unplanned pneumothorax. A lighted right-angle breast retractor as well as a narrow Deaver retractor are employed for optimal exposure. The video thoracoscope is used for its magnification, as an excellent light source, and for facilitating teaching. The patient is placed in the lateral position with an axillary roll under the "down" side. The "up" side arm is wrapped and elevated over a traction apparatus with a 2-pound weight. Two special arm holders (technicians) are employed to keep the arm at 90 degrees from the chest wall, avoiding hyperabduction or hyperextension of the shoulder. Care is taken to relax the arm as often as necessary. The arm, axilla, and chest wall are prepared and draped.

---

Chair of Cardiovascular & Thoracic Surgical Research, Education & Clinical Excellence, Baylor University Medical Center, and Professor of Cardiovascular and Thoracic Surgery (Clinical), University of Texas Southwestern Medical School, Dallas, Texas.

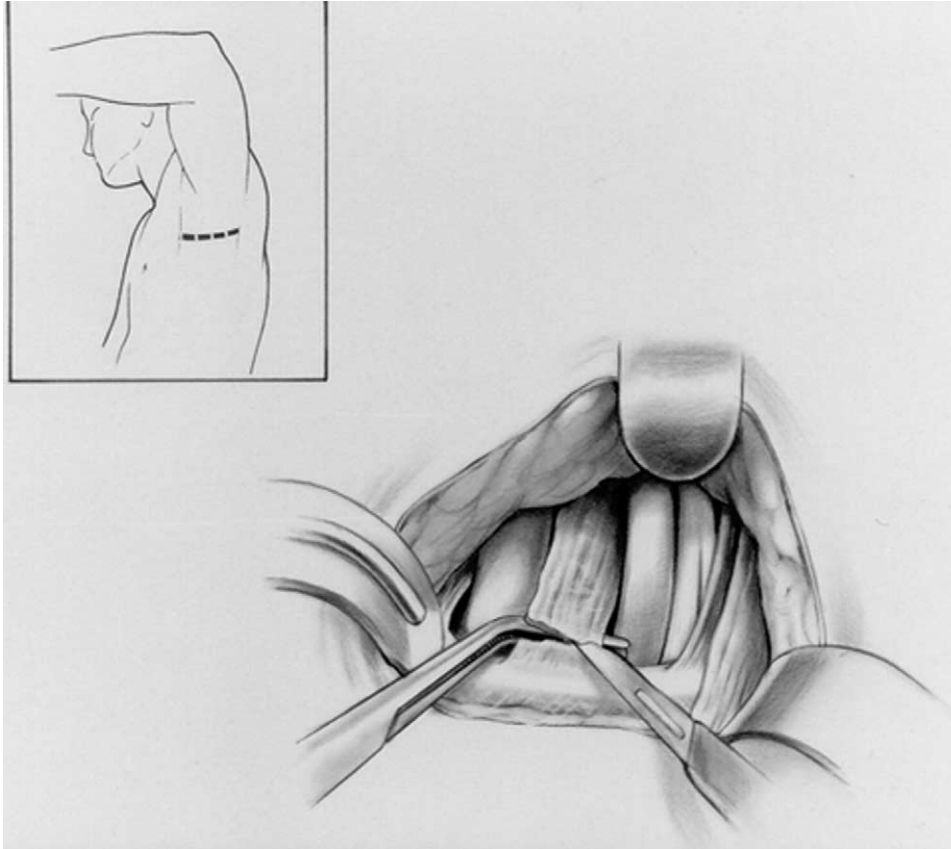
Address reprint requests to Dr. Harold C. Urschel, Jr., MD, Chair of Cardiovascular & Thoracic Surgical Research, Education & Clinical Excellence, Baylor University Medical Center, 3600 Gaston Avenue, Suite 1201 Barnett Tower, Dallas, Texas 75246. E-mail: drurschel@earthlink.net

# THORACIC OUTLET SYNDROME

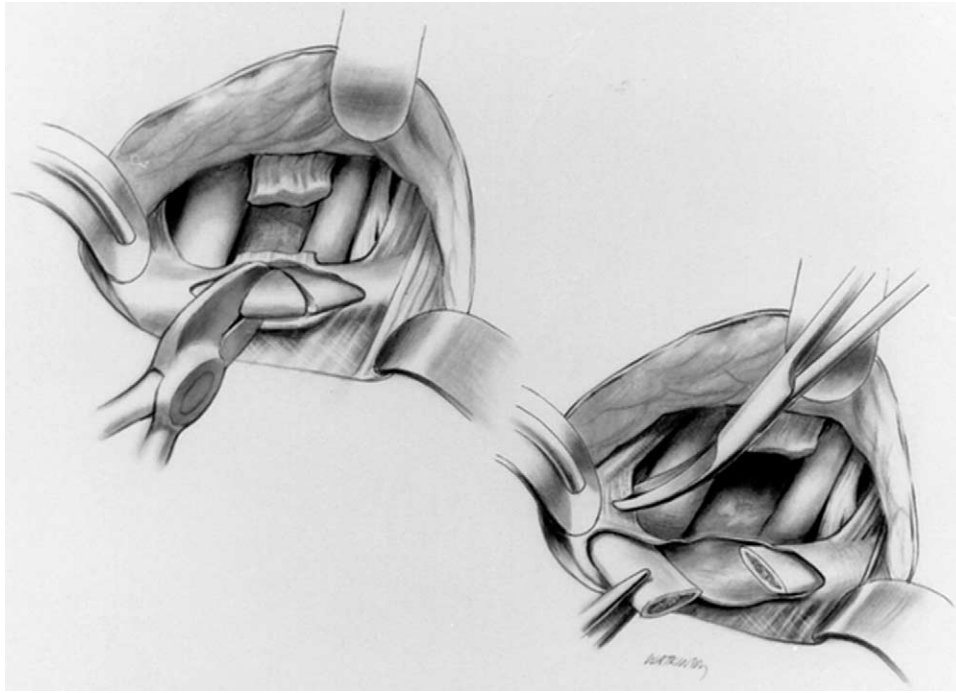


**Figure 1** The relation of muscle, ligament, and bone abnormalities in the thoracic outlet that may compress neurovascular structures against the first rib.

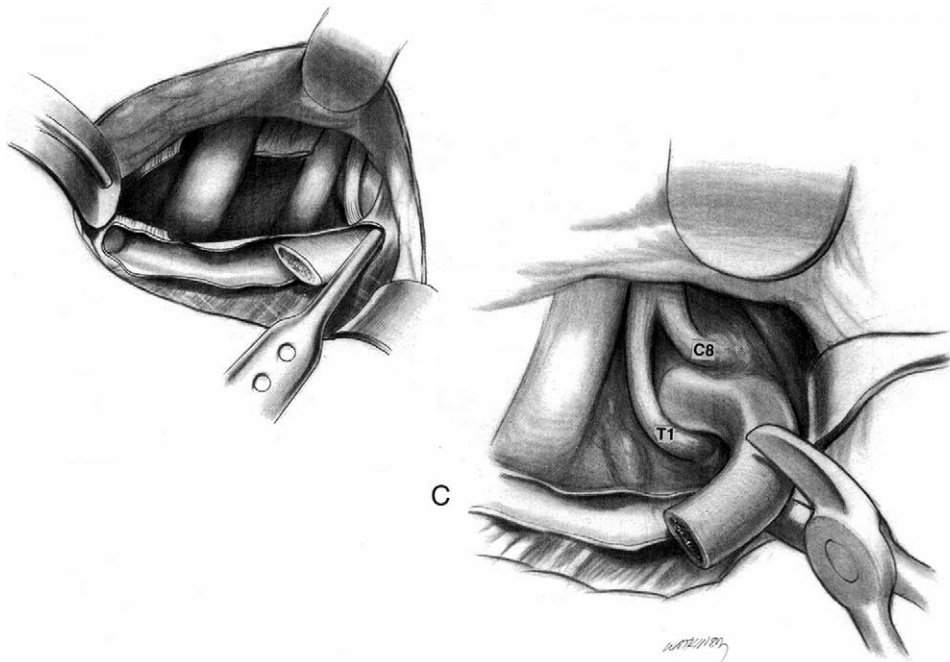
## Operative Technique



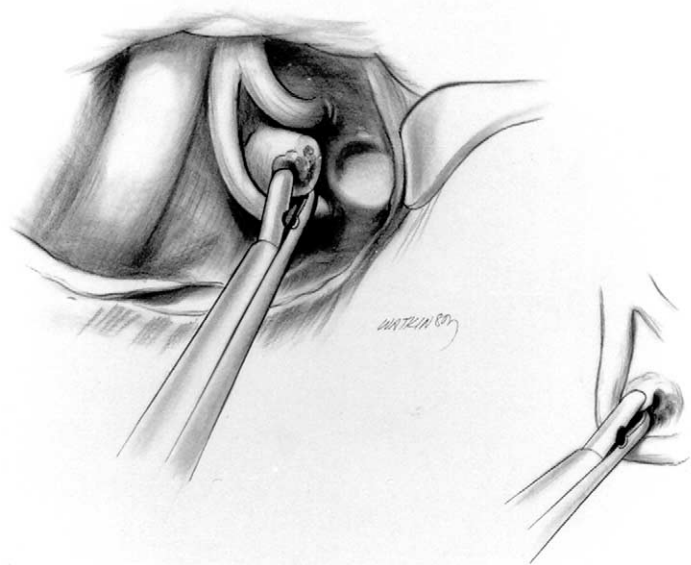
**Figure 2** The incision for the transaxillary resection is made transversely below the axillary hairline between the pectoralis major and latissimus dorsi muscles (see inset).<sup>9</sup> The incision is carried directly to the chest wall without angling up toward the first rib. When the chest wall is encountered, the dissection is directed superiorly to the first rib, identifying the intercostal brachial nerve as it exits between the first and second ribs. The nerve is preserved by retracting it anteriorly or posteriorly. (Division of this nerve produces up to 6 months of paresthesias on the inner service of the upper arm, which may be very disturbing to the patient). If adhesions are present, it is necessary to perform a careful lysis of these. In this instance the neurovascular structures are dissected carefully off the chest wall in order to visualize the first rib. The first rib is dissected subperiostally with a Shaw-Paulson periosteal elevator and the scalenus anticus muscle identified. The right-angle clamp is placed behind the muscle, being careful not to injure the subclavian artery or vein. The scalenus anticus muscle is divided near its insertion on the first rib. (This procedure avoids injury to the phrenic nerve, which courses from laterally to medially across the anterior surface of the muscle.)



**Figure 3** After dividing the scalenus anticus muscle, the first rib is dissected free subperiostally and separated from the pleura. A triangular piece of the rib is removed in the avascular area. The vertex of the triangle removed is at the scalene tubercle. The anterior part of the rib is then resected back to the costocartilage of the sternum by dividing the costoclavicular ligament (CCL) and then resecting it.



**Figure 4** The posterior part of the rib is dissected subperiostally to the transverse process, by using the Shaw-Paulson periosteal elevator to remove the scalenus medius muscle which is attached to the first and the second rib. The rib is carefully divided near the transverse process with a pair of rib shears. The head and the neck of the rib are then removed with the Urschel reinforced pituitary and Lexell rongeurs from between the C8 and T1 nerve roots. Care is taken to avoid injury to these nerve roots. It is important to remove the whole rib, otherwise recurrence frequently occurs from the osteoblasts or osteocytes regenerating from the end of the rib. Regenerated bone from the periostium rarely produces any compressive symptoms.



**Figure 5** After visualizing the transverse process articulation, the head and neck of the rib are carefully removed with an Urschel reinforced pituitary rongeur. It is important to remove the complete head and neck of the rib to minimize regeneration. Care is taken not to injure the T1 nerve root below or the C8 nerve root above. Following complete removal of the first rib, neurolysis of C7, C8 and T1 nerve roots is performed with magnification and the middle and lower trunks of the brachial plexus (BP) also undergo the same procedure. A video thoracoscope expedites the procedure because of the magnification and increased light. The scalenus anticus muscle is resected back up into the neck so that it will not reattach to Sibson's fascia or the pleura. Bands and adhesions are removed from the axillary-subclavian artery and vein so that they are completely free. Hemostasis is secured. Depo-Medrol and SeptraSeal (or hyaluronic acid) are placed in the area of neurolysis. The pleura is generally opened and a small tube placed through the incision and into the pleural cavity so that no hematomas accumulate around the area of dissection. Interrupted and running 2 to 0 and 3 to 0 vicryl suture and a subcuticular 3 to 0 vicryl are placed.

## References

1. Rob CG, Standeven A: Arterial occlusion complicating thoracic outlet compression syndrome. *Br Med J* 46:709, 1958
2. Urschel HC Jr, Razzuk MA: Neurovascular compression in the thoracic outlet: changing management over 50 years. *Ann Surg* 228:609, 1998
3. Urschel HC Jr: The transaxillary approach for treatment of thoracic outlet syndrome. *Chest Surg Clin North Am* 9:771-780, 1999
4. Urschel HC Jr, Razzuk MA: Paget-Schroetter syndrome: what is the best management? *Ann Thor Surg* 69:1663-1669, 2000
5. Urschel HC Jr, Patel AN: Paget-Schroetter syndrome therapy: failure of intravenous stents. Presented at STSA Meeting, Miami, FL, Nov 8, 2002. *Ann Thorac Surg* 75:1693-1696, 2003
6. Urschel HC Jr, Razzuk MA: Upper plexus thoracic outlet syndrome: optimal therapy. *Ann Thorac Surg* 63:935-939, 1997
7. Urschel HC Jr: Reoperation for thoracic outlet syndrome. In Eschaspasse H, Dalarue N (eds): *International Trends in General Thoracic Surgery Vol II*. Philadelphia, PA, C.V. Mosby Company, 1986.
8. Urschel HC Jr: Video-assisted sympathectomy and thoracic outlet syndrome. *Chest Surg Clin North Am* 3, 1993
9. Urschel HC Jr, Cooper JC: *Atlas of thoracic surgery*. New York City, Churchill Livingstone, 1995.